



HKSH
Healthcare Medical Centre
養和醫健 專科中心

OCT Optical Coherence Tomography



For enquiries and appointments, please contact us

HKSH Healthcare Medical Centre Ophthalmology Centre

📍 Level 21, One Pacific Place
88 Queensway, Hong Kong
☎ (852) 2855 6700 🖨 (852) 2523 7660
✉ eye@hksh-healthcare.com

Service Hours (by appointment only)

Monday to Friday: 9:00 am - 5:00 pm
Saturday: 9:00 am - 1:00 pm
Closed on Sundays and Public Holidays

www.hksh-healthcare.com

A member of HKSH Medical Group © HKSH Healthcare Limited. All rights reserved.

OPH.1211.HC-02-112016(P)

Ophthalmology Centre
眼科中心

www.hksh-healthcare.com

What Is Optical Coherence Tomography?

A low energy pin-point near-infrared laser beam is projected and scanned across designated structures of the eye ball including the cornea, anterior segment and the back of the eye (retina) in a pre-defined pattern. Sensors will then detect the reflected light, after which the advanced computerised algorithm will analyse the reflected light (low-coherence interferometry) which has been changed in accordance with structural layers of the retina and its nerve fibre layer.

What Is the Merit of OCT Scanning?

In a non-invasive manner, posterior segment OCT system can analyse the layered structures of the retina (which is the photosensitive structure of our eyes, like the film in a camera) with a resolution reaching below 5 microns. The optic nerve and the anterior segment of the eye can be examined in greater details. The anterior segment OCT system can analyse the cornea, iris, anterior segment angles and anterior part of the lens.

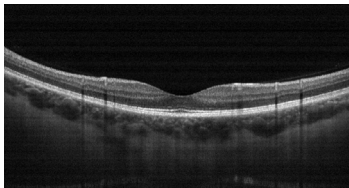
Clinical Applications

Since its inception, OCT has helped ophthalmologists tremendously in understanding the pathology of many complicated retinal and optic nerve diseases. It can facilitate diagnosis, assessment and progress monitoring of many eye problems before and after treatment, including:

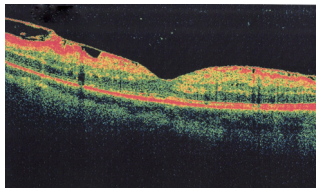
1. Macula diseases: e.g. full thickness/lamellar macular hole, macular detachment, macular schiasis, high myopic macular pathology, age-related macular degeneration, central serous chorioretinopathy, macular edema, macular pucker etc.
2. Retinal problems: e.g. diabetic retinopathy and maculopathy, epiretinal membrane etc. Retinal/macular edema secondary to retinovascular disease
3. Retinal nerve fibre layer pathology: e.g. glaucomatous retinal nerve fibre damage and thinning
4. Optic nerve pathology: e.g. disc cupping in glaucomatous optic neuropathy, optic disc pit, disc drusens, etc.
5. Assessment of ganglion cell complex thickness at the macula, which can help diagnose glaucoma early
6. Assessment of the anterior chamber depth and angle, and monitoring of its change (e.g. in narrow angle or occludable angle suspect)
7. Assessment of cornea diameter, cornea thickness, the cornea flap after corneal-refractive surgery (e.g. LASIK) and many other corneal pathologies (e.g. keratoconus)
8. Assessment of the surface of the lens in the eye and also that of intraocular lens after cataract surgery

Overall, the development of OCT has greatly enhanced the quality care and management of many eye patients in a fast, non-invasive and reproducible way.

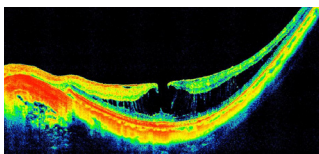
Please consult your ophthalmologists for further details to assess whether OCT can facilitate the treatment of your eye condition.



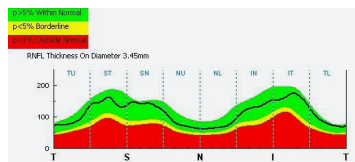
Normal macular



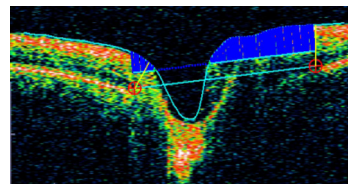
Epiretinal membrane



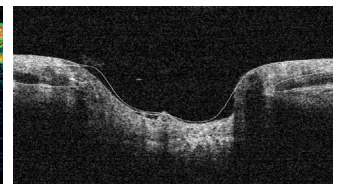
Macular hole and edema



Measurement of retinal nerve fibre layer thickness



Normal optic nerve



Large disc cup in glaucoma patient